

Diabetic Neuropathic Foot

Ashok Kumar Das*

Diabetes mellitus is a disease of complications and Diabetic Foot Syndrome is an important problem confronting society and health professionals. In USA one in four diabetics sustains foot ulcer and 40% of them lose their feet [1]. It accounts for 70% of non-traumatic amputations. In Joslin Diabetes Clinic, 25% admissions are due to foot ulcers. In Indian scene, the data is limited. In the study conducted in JIPMER [2], diabetic foot ulcers constituted 1.525 hospital admissions per thousand out-patient attendance.

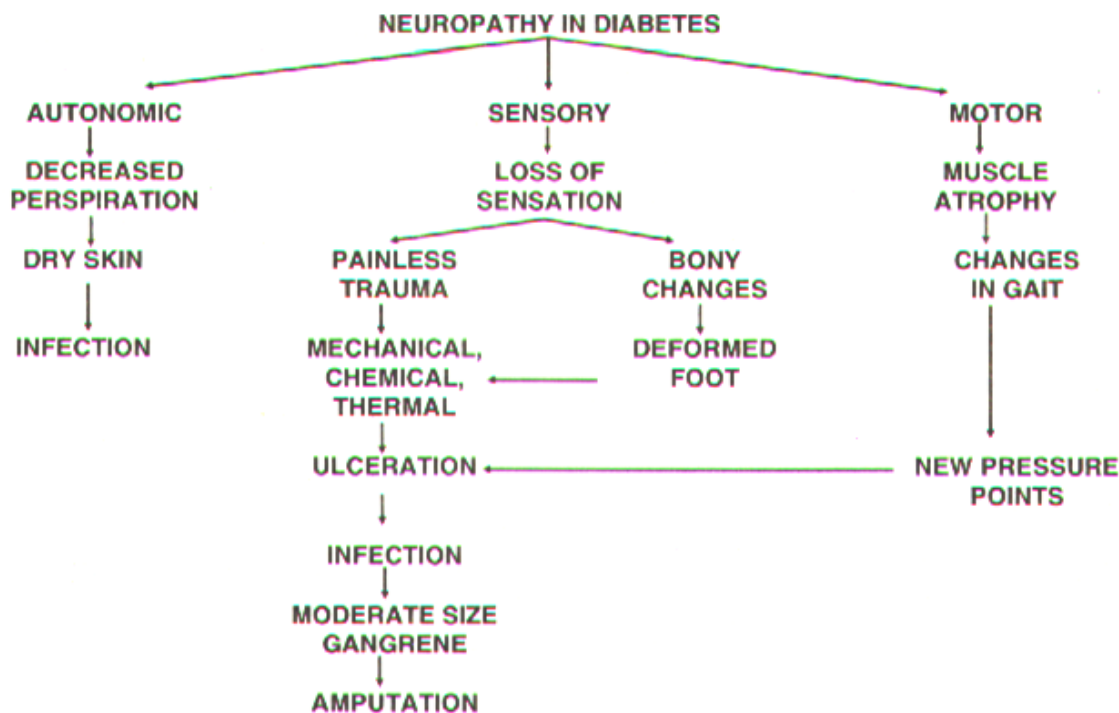
Peripheral sensory neuropathy is the largest single cause of foot ulceration[3]. Neuropathic foot is at great risk from minor trauma, though pressure is the main cause of neuropathic ulceration [4]. Low, but sustained pressure, as from tight shoes, leads to painless ischaemia and tissue breakdown. Repetitive moderate stress, as induced during

walking is a common cause of ulceration and the reason for the predominance of such lesions below metatarsal heads and other pressure points.

Prevalence data for diabetic neuropathy are sparse. An extensive study by Pirat of nearly 4500 patients showed a prevalence rate ranging from 7% for patients within one year of diagnosis to 50% for those with diabetes of more than 25 years-duration [5]. In this study, neuropathy was defined as loss of Achilles reflex with symptoms and objective signs of polyneuropathy.

In a study of 200 patients, it was found that severity of polyneuropathy correlated with height of patients rather than obesity [6]. Subsequently it was proved that sites farthest from central nervous system were more affected as supply channels for axoplasmic flow down the nerves to these sites were the longest and so more vulnerable.

Table 1
Aetiopathogenesis of Diabetic Neuropathic Foot Ulcer



* From Department of Medicine, Jawaharlal Institute of Post-Graduate Medical Education and Research, Pondicherry – 605 006.

Table 2
CLASSIFICATION OF DIABETIC NEUROPATHIC FOOT:

Classification of Diabetic Neuropathic Foot (7)

1. Classification based on fibre type

Symmetrical distal polyneuropathy

* Small fibre

* Mixed small and large fibre

* Large fibre

2. Clinical classification

Diabetic neuropathic cachexia

Painful painless leg

Diabetic pseudotabes

Mixed distal sensory-motor neuropathy

Autonomic foot

Insensitive foot

1. Classification Based on Fibre Type

Symmetrical Distal Polyneuropathy

Small fibre type: In small fibre neuropathy painful paraesthesias, most commonly over lower limbs are the characteristic symptoms. Pain may be dull, burning, aching, lancinating or cramp like; paraesthesias, may manifest as a sensation of coldness, numbness or tingling. There may be associated diminution of pain and temperature perception in lower limbs in stocking distribution. Autonomic dysfunction is most prevalent in this type of neuropathy, since autonomic neuropathy is also a small fibre neuropathy.

Mixed small and large fiber: This is the most common variety of painful diabetic neuropathy. In addition to the features of small fibre neuropathy, there is usually loss of ankle jerk, impaired position and vibration sense, sensory ataxia and autonomic involvement.

Large fibre neuropathy: In this, there is loss of ankle reflexes, decreased position and vibration sense and sensory ataxia.

2. Clinical Classification

Diabetic Neuropathic Cachexia [8]

This is a type of distal polyneuropathy first described by Ellenberg in 1974. The two outstanding features at diagnosis were weight loss and severe pain leading to a diagnosis of metastatic carcinoma or carcinomatous neuropathy in each of the six cases described by him. The patients were all males in the sixth decade and had bilateral symmetrical peripheral neuropathy, anorexia, impotence, emotional disturbance, mild diabetes, simultaneous onset of diabetes and neuropathy, absence of other specific complications and uniformly a spontaneous recovery in about one year.

Painful Painless Leg Syndrome - John Ward [9]

Ward described the painful painless leg in which the patient experiences pain or paraesthesia but on neurological examination has absent pain sensation. Such patients are at greatest risk of painless injury to the feet.

Diabetic Pseudotabes

In some patients the clinical picture may be dominated by deep sensory loss, ataxia and loss of bladder sensation with slight weakness of limbs resembling tabes dorsalis. The similarity is even close if lancinating pains in the legs, unreactive pupil and neuropathic arthropathy is found. This has been described as "diabetic pseudotabes".

Mixed Distal Sensory Motor Neuropathy [10]

Middle aged to older patients usually present with mildly diminished strength and size of intrinsic muscles of hands and feet associated with longstanding distal symmetrical sensory neuropathy. This type of neuropathy may result in debilitating pain or ulceration.

Autonomic Foot

Autonomic neuropathy may lead to diabetic foot syndrome as described later.

Insensitive Foot

Absence of sensation over the feet, "insensitive foot", makes it prone to trauma and vulnerable to the development of diabetic neuropathic foot.

Evaluation of Peripheral Neuropathy

Clinically-touch, pressure, pain, temperature, vibration, position sense and ankle jerk should be tested.

Laboratory

1. Electromyography should be done to delineate muscle or nerve pathology.
2. Motor nerve conduction velocity is determined to look for motor neuropathy.
3. Sensory neuropathy
 1. Large fibre modality - vibration perception threshold stimulation is done using a Bioaesthesiometer.
 2. Small fibre modality - Marstock stimulator based on Piezo electric phenomenon may be used for quantitative estimation of thermal sensitivity.

Mechanism of Foot Infection in Diabetic Neuropathic Foot may be

1. Structural Deformity

- 1) Paresis of long and short flexors and intrinsic muscles of the legs lead to high pressure acting at a localised site.
- 2) Due to paretic muscles, there is decreased toe loading with shift of vertical pressure medially. Hence 70% of normal toe loading is transmitted through hallux accounting for the common site of ulcer on head of metatarsals.
- 3) "Cock-up" deformities/varus deformities may be associated.
- 4) Callous formation - James Crabbe [11] in his description of diabetic foot observes that neuropathic foot invariably starts with callous formation.

2. Neurogenic Arthropathy

Rapid progression to advanced deformity in the neuropathic foot can occur with trivial trauma. Initially, there is a painful joint with effusion which evolves into painless disorganised joint.

3. Spontaneous Dislocation

Newman [12] described a series of six NIDDM patients with neurological manifestation with spontaneous dislocation of talonavicular and tarsometatarsal joint. It may be a variant of Charcot's joint.

4. Insensitive Feet

Loss of sensation in feet makes diabetics prone to recurrent trauma.

The initiating factors in the development of diabetic foot are usually trauma and burns. In the third world countries tat bites may be an important causative factor [13].

Autonomic Neuropathy in Diabetic Foot Syndrome

Autonomic functions are carried out by small fibres and are affected by diabetes. Gustatory sweating if present is pathognomonic of autonomic neuropathy. Other features may be exercise intolerance, orthostatic hypotension, gastroparesis, diabetic diarrhoea and impotence.

Role of Autonomic Nervous System Involvement in Diabetic Foot Syndrome

- 1) Sympathetic denervation [14, 15] open up AV shunts, thereby short-circuiting nutritive blood flow. This is suggested by the fact that oxygen saturation in pedal veins is similar to that of brachial artery in these patients. Furthermore increased venous pressure secondary to AV shunting leads to local oedema augmenting hypoxia.

- 2) Increased blood flow causes bone rarefaction making them prone to fracture with trauma.
- 3) Corbin et al [16] showed that patients with autonomic neuropathy are more often found amongst patients of painless neuropathic foot associated with recurrent ulceration.
- 4) Anhydrosis leads to cracks in the skin, which predisposes to infection.
- 5) Goodman [17] recognised clearly "Anhydrosis syndrome" with intolerance to heat and anhydrosis below waist. These patients are prone to foot ulceration secondary to infected sweatless feet.

Table 3

Patients at Risk of Foot Ulceration

1. History of previous ulceration
2. Presence of
 - * Peripheral neuropathy
 - * Peripheral vascular disease
 - * Limited joint mobility
 - * Bony deformity
 - * Diabetic nephropathy
 - * Diabetic retinopathy
 - * Alcoholism
3. Patients who live alone or who are elderly (more than 70 year age).

Clinical Features of Neuropathic Foot [18]

In neuropathic foot somatic and autonomic nerve fibres have been damaged but the circulation is intact and the pulses are palpable resulting in a warm, numb, dry foot. The neuropathic foot has 3 main complications:

- I. Neuropathic ulcer
- II. Neuropathic (Charcot) joint
- III. Neuropathic oedema

Table 4

Difference Between Neuropathic and Ischaemic Foot

	Diabetic Non-ischaemic Neuropathic foot	Ischaemic Foot
Incidence	Common	Less common, especially in India
Site	Plantar aspect of Tarsometatarsal Joints and pressure sites	Side of digits/foot
Temperature	Warm	Cold
Pain	Painless	Painful
Peripheral pulses	Bounding	Absent
Ankle Brachial	More than 1.1	Less than 0.6
Prognosis	Fair	Bad

i) Neuropathic Ulcer

It occurs at sites of high mechanical pressure on the plantar surface of the feet. The predisposing

factors have been mentioned above. Repetitive mechanical forces lead to inflammatory autolysis and sub-keratotic haematoma, which eventually break through to the skin surface forming an ulcer. Ulcers are often infected by Staphylococci, Streptococci, coliforms or anaerobes. Extensive tissue loss and gangrene may finally result.

Management

1. Excess callus should be paired away with a scalpel by a trained chiropodist/interested diabetic nurse.
2. Oral antibiotics appropriate to the sensitivity of the infecting organism to be given until the ulcer has healed if the ulcer is superficial and there is no cellulitis. If cellulitis is present, the following regimen has to be followed:
 - ❖ Admit to the hospital
 - ❖ Bed rest
 - ❖ Antibiotics, "General cover" regimen or specific if organism is known
 - ❖ Urgent surgical drainage of pus and debridement of tissue
 - ❖ Pus for culture and adjust antibiotics accordingly
 - ❖ Consider ray amputation of digits if bone is destroyed
 - ❖ Ensure tight glycaemic control using intravenous insulin if necessary

ii) Neuropathic (Charcot) Arthropathy

This is diagnosed by 3 main features: -

1. History of trauma – often minor
2. Presence of unilateral warmth and swelling
3. Positive radiographic or bones scan findings

Radiographic Finding

Initial radiological examination may be normal but subsequent films show evidence of fracture, osteolysis and fragmentation of bone followed by new bone formation and finally subluxation and disorganisation of the joint. Bone scans are more sensitive indicators of new bone formation than radiography and should be used to confirm the diagnosis.

The tarsometatarsal joints are most commonly involved.

Management

Initial management comprises of immobilisation and unloading of the injured limb using non-weight-bearing crutches or total contact plaster casts. This is continued until oedema and warmth has subsided. Foot should be gradually mobilised using a moulded insole in a custom fitted shoe.

iii) Neuropathic Oedema

This is fluid accumulation in feet and lower legs which is associated with severe peripheral neuropathy and not explicable by other causes such as cardiac failure or hypoalbuminaemia.

It is extremely rare and may be due to abnormal vasomotor function following autonomic denervation causing arteriovenous shunting and disturbances in hydrostatic pressure in microcirculation.

Management

The sympathomimetic drug ephedrine (30mg q 8 hourly) has been found to be effective probably by reducing peripheral blood flow and increasing urinary sodium excretion.

Treatment of Diabetic Foot

a) Grading of Diabetic Foot Ulcer

William Wagner has graded diabetic foot into 6 grades: [19]

Grade 0: No open lesion. Deformities such as claw foot or hallus valgus may be found.

Grade 1: Full thickness loss of skin with or without bony prominences.

Grade 2: Open lesion penetrates to tendon, bone or joints.

Grade 3: Deeper lesions with osteomyelitis, pyoarthrosis, plantar space abscess or infections of tendon and tendon sheath.

Grade 4: Gangrene in some portion of toe or forefoot. There may be surrounding cellulitis and the gangrene may be wet or dry.

Grade 5: Gangrene involves the whole foot or such a percentage that no local procedure is possible and higher amputation is needed.

b) Medical

- Treatment comprises of good blood sugar control and treatment of infections, rest and plaster cast.
- Specific measures are:
Once healed, diabetics need different types of footwear. They are: [20]
 - * Moulded insole
 - * Extra depth shoes
 - * Rocket sole shoes
 - * Polymer insole material shoes
 - * Custom-made foot wear
 - * Cobra pad

It has been shown that 86% of neuropathic ulcers healed with special shoes. Relapse rate was 26% compared to 83% who preferred to wear their own shoes.

Total contact casting – Mullet [21] in a controlled study found that total contact casting had better results with ulcers healing faster with fewer infections as compared to traditional dressing treatment.

Preventive Aspects

a) Foot Care

- i) Identification of individuals at high risk.
- ii) Follow up of the patients including examination of foot at each visit.
- iii) Consultation with speciality services including orthopaedics and chiropody.
- iv) Use of modified footwear.

b) Other Measures

Controlling the other risk factors like: -

- i) Ischaemia/peripheral vascular disease
 - * Smoking
 - * Hyperlipidaemia
 - * Hyperglycaemia
- ii) Peripheral neuropathy
 - * Hyperglycaemia
- iii) Infection

This may decrease the morbidity and mortality of diabetic foot syndrome.

c) Do's and Dont's of Foot Care in Diabetics

- i) Don't smoke
- ii) Inspect toes, especially between toes daily for blisters, cuts
- iii) Wash feet daily and dry carefully, especially between toes
- iv) Use lubricants for dry skin
- v) Avoid extremes of temperature. Test water before bathing
- vi) Don't use chemicals for removing calluses and corns
- vii) Wear properly fitted shoes
- viii) Don't walk bare footed
- ix) Cut nails straight across
- x) Cover your feet during sleep

CONCLUSION

Diabetic neuropathic foot is one of the important causes of morbidity amongst diabetics in our country. Though limb loss occurs mostly in ischaemic diabetic foot, few non-ischaemic neuropathic foot ulcer patients may require amputation. The main reasons for this are late arrival to the hospital, gross neglect and severe infection. Trauma to insensitive feet appears to be the most common inciting factor. Most of the patients present with moderate/severe grades of ulceration showing colossal lack of foot care and majority have dismal levels of blood glucose at the time of presentation.

It is worth mentioning that most of diabetic neuropathic foot ulcer patients in developing countries like ours are illiterate with little awareness and almost no diabetic education [22]. Diabetic neuropathic foot syndrome warrants a team approach and adequate patient education.

REFERENCES

1. Clinics in endocrinology and metabolism: Long term complications of diabetes, 1986; 889-916.
2. Das AK, Prasad Niraj. Diabetic foot disease at JIPMER. Dissertation for M. D. 1991.
3. Thompson FJ et al. The impact of multidisciplinary approach to diabetic foot problems. *Diabetologia*. 1990; 33: A130.
4. Brand PW. The diabetic foot in diabetes mellitus – Theory and Practice, 3rd edn. Ellenberg M. Rifkin H (eds.). New York, Medical Examination Publishing, 1983; 829-50.
5. Pirat J. Diabetes mellitus and its degenerative complications. *Diabetes Care*. 1978; 1: 168-88.
6. Sosenko Jay M, Gadia MT, Fowenier ATT et al. Body structure as a risk factor for diabetic sensory neuropathy. *Am J Med* 1986; 80: 1031-4.
7. Yadollah Harati. Review of diabetic peripheral neuropathy. *Ann Int Med*. 1987; 107: 546-59.
8. Ellenberg M. Diabetic neuropathic cachexia. *Diabetes*. 1974; 23: 418-23.
9. Ward JD. The diabetic leg. *Diabetologia*. 1982; 22: 141-50.
10. Fry IK, Hardwick C, Scool GW. Diabetic neuropathy: A survey and follow up of 66 cases. *Guy's Hosp Rep*. 1962; 111L: 113-20.
11. James M, Crabbe C. Diabetic complications, scientific and clinical aspects. Churchill Livingstone Publication, 1987.
12. Newman JH. Spontaneous dislocation in diabetic neuropathy. *J Bone and Jt Surg*. 1979; 61B: 487.
13. Cookes A. Rat bites in diabetic foot in West Indies. *Br Med J*. 1989; 298: 868.
14. Watkin PJ, Edmonds ME. Autonomic neuropathy. Blood flow in the diabetic foot. A symposium, September 1981; 22-4.
15. Boulton AJM, Scarpello JHB, Ward JD. Venous oxygenation in diabetic neuropathic foot. Evidence of arteriovenous shunting. *Diabetologia*. 1982; 22: 6-8.

16. Carbon DOC, young RJ, Morrison DS et al. Blood flow in foot. Polyneuropathy and foot ulceration in diabetes mellitus. *Diabetologia*. 1987; 30: 468-73.
17. Goodman JJ. Diabetic anhydrosis. *Am J Med*. 1966; 41: 831.
18. Edmonds Michael E, Ali VM Foster. Diabetic foot in textbook of diabetes, edited by John Pickup and Gareth Willams. 1991; 735-44.
19. Medical clinics of North America on diabetes: Diabetic foot syndromes 1989; 72: 1513-30.
20. Ralph Ger. Prevention of major amputations in the diabetic patient. *Arch Surg*. 1985; 12; 1317-20.
21. Muller Michael J, Diamond Jay E, Sina David R, Core et al. Total contact casting in treatment of diabetic plantar ulcers, controlled clinical trial. *Diabetes Care*. 1989; 12: 384-8.
22. Chandalia H.B., Das A.K. Detection of the diabetic foot at risk on Diabetes 1988, Eds. Larkins R.G., Zimmet P.Z., Chisholm D. J., Excerpta Medica, ICS 800, Amsterdam, 1989; 1057-62.